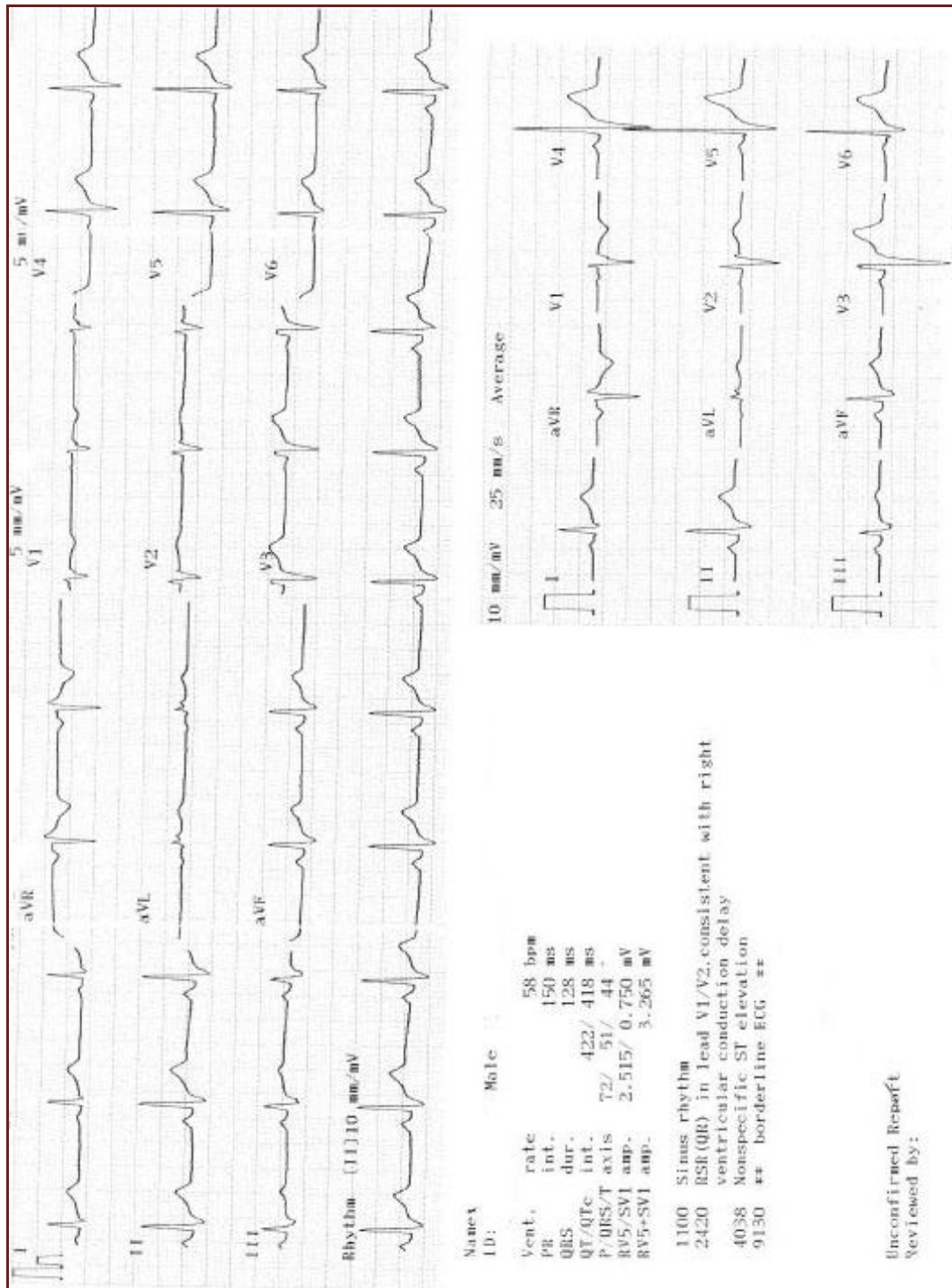


Quiz ECGs

Quiz ECG 1

05 June 2006 (Most recent ECG)



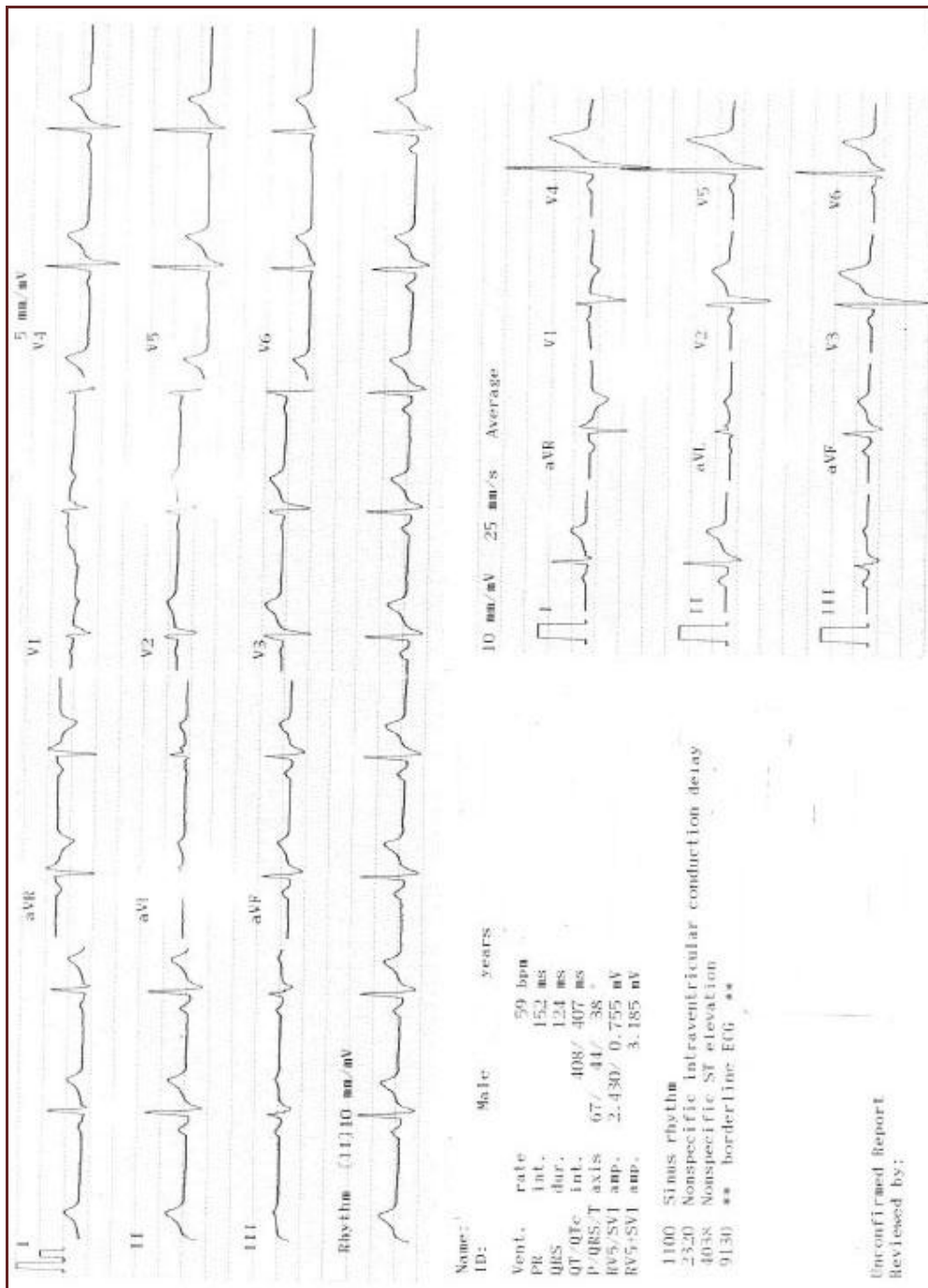
36 year old male, class 1 medical certificate applicant with calculated < 10% 5-year cardiovascular risk.

Electronic ECG report conclusion: Sinus rhythm, RSR(QR) in leads V1/V2, consistent with right ventricular conduction delay. Nonspecific ST elevation. Borderline ECG. Cardiologist conclusion: Normal ECG except for previously seen intraventricular conduction defect.

Issued unrestricted class 1 medical certificate.

Quiz ECG 2

07 June 2005 (One year ago)



35 year old male, class 1 medical certificate applicant.

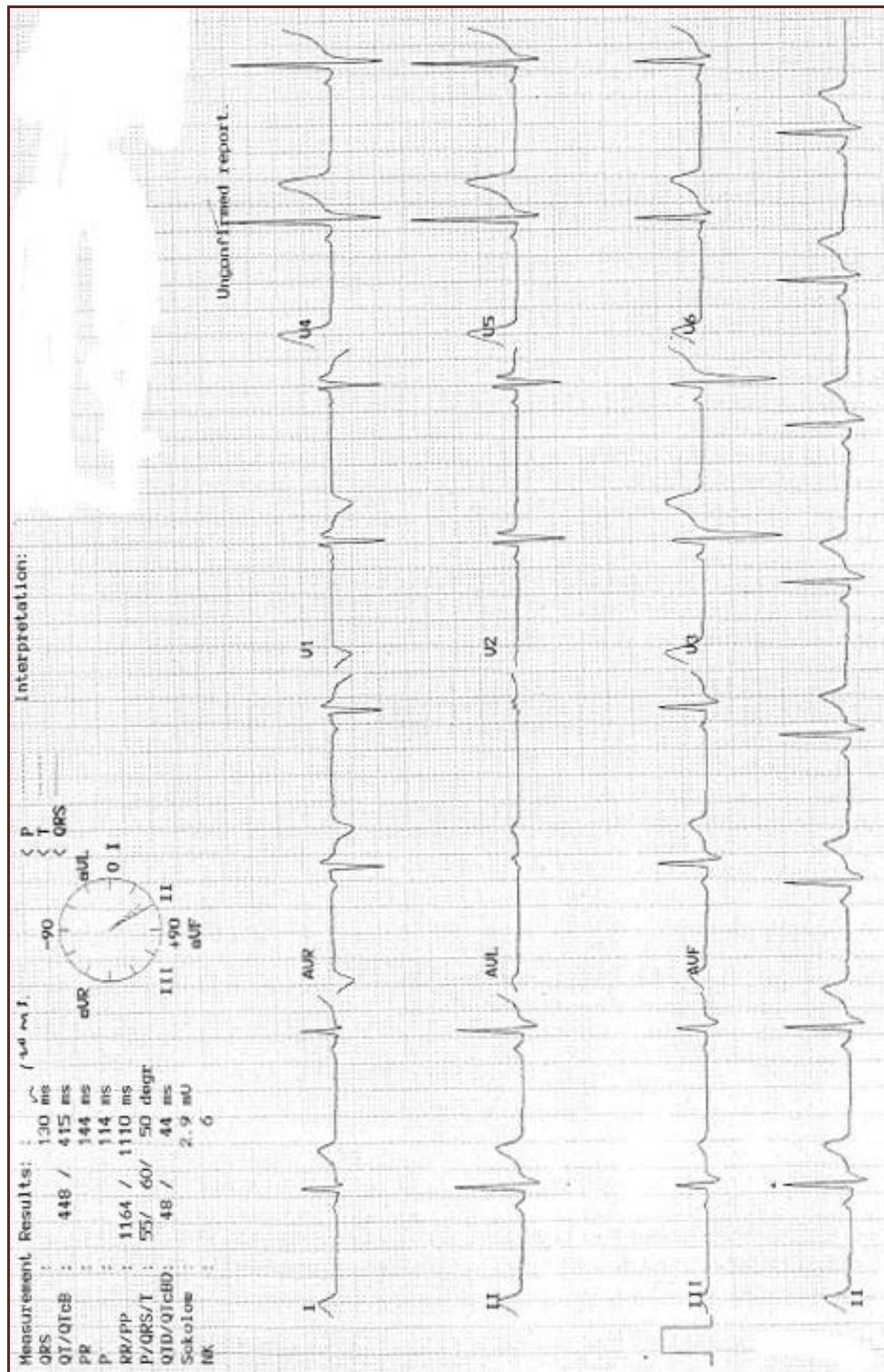
Electronic ECG report conclusion: Sinus rhythm, Nonspecific intraventricular conduction delay, Nonspecific ST elevation, borderline ECG. Cardiologist report: Normal ECG except for previously seen intraventricular conduction defect.

Repeat echocardiogram, following-up on previous echo, undertaken in November 2004, was completely normal.

Issued unrestricted class 1 medical certificate.

Quiz ECG 3

22 November 2002 (Four years ago)



32 year old male, class 1 medical certificate applicant.

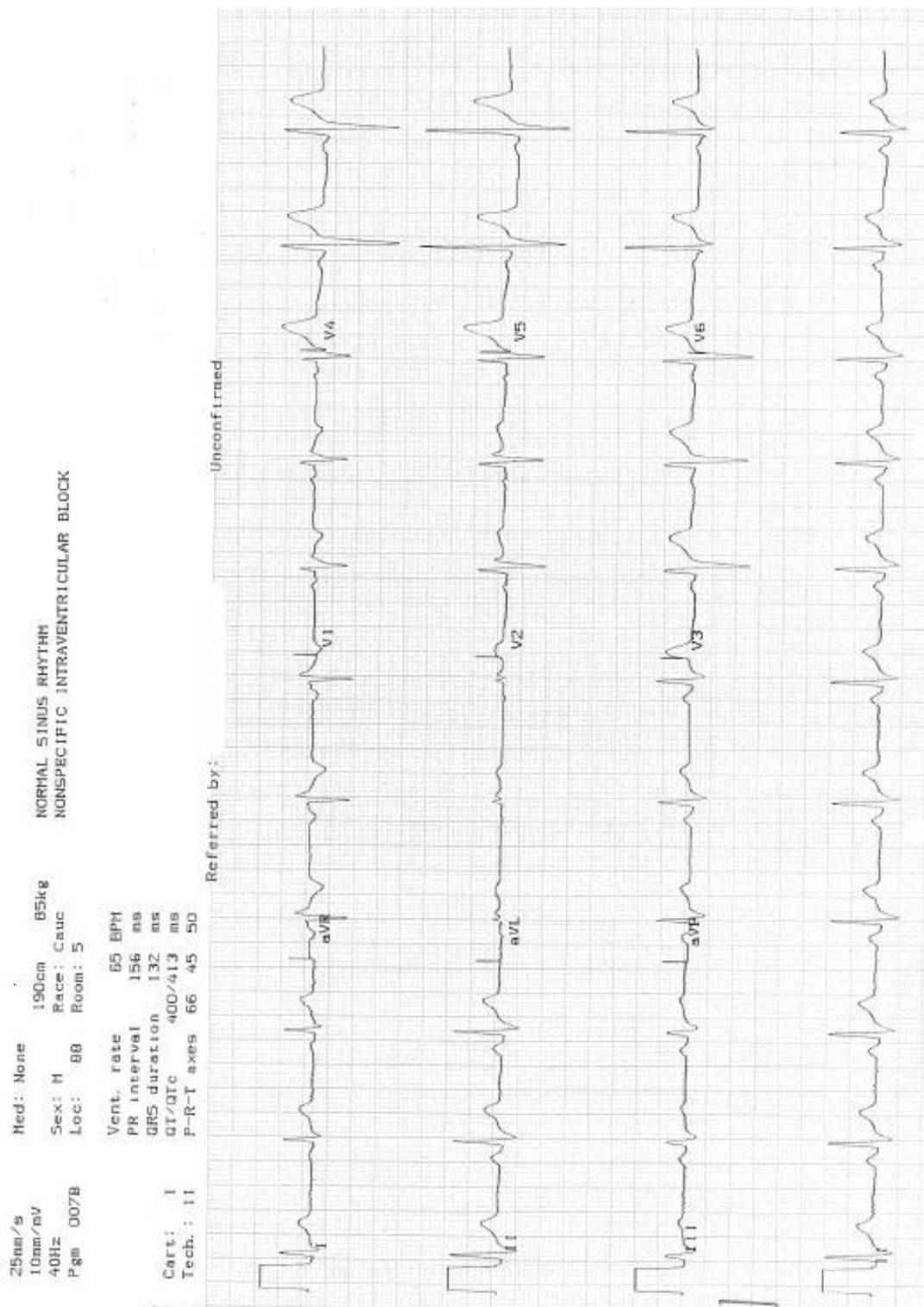
Cardiologist report: Right intraventricular conduction blocks – otherwise normal.

2002 2D echocardiography completely normal. Cardiologist recommends repeat echo in two years.

Issued unrestricted class 1 medical certificate.

Quiz ECG 4

07 August 2000 (Six years ago)



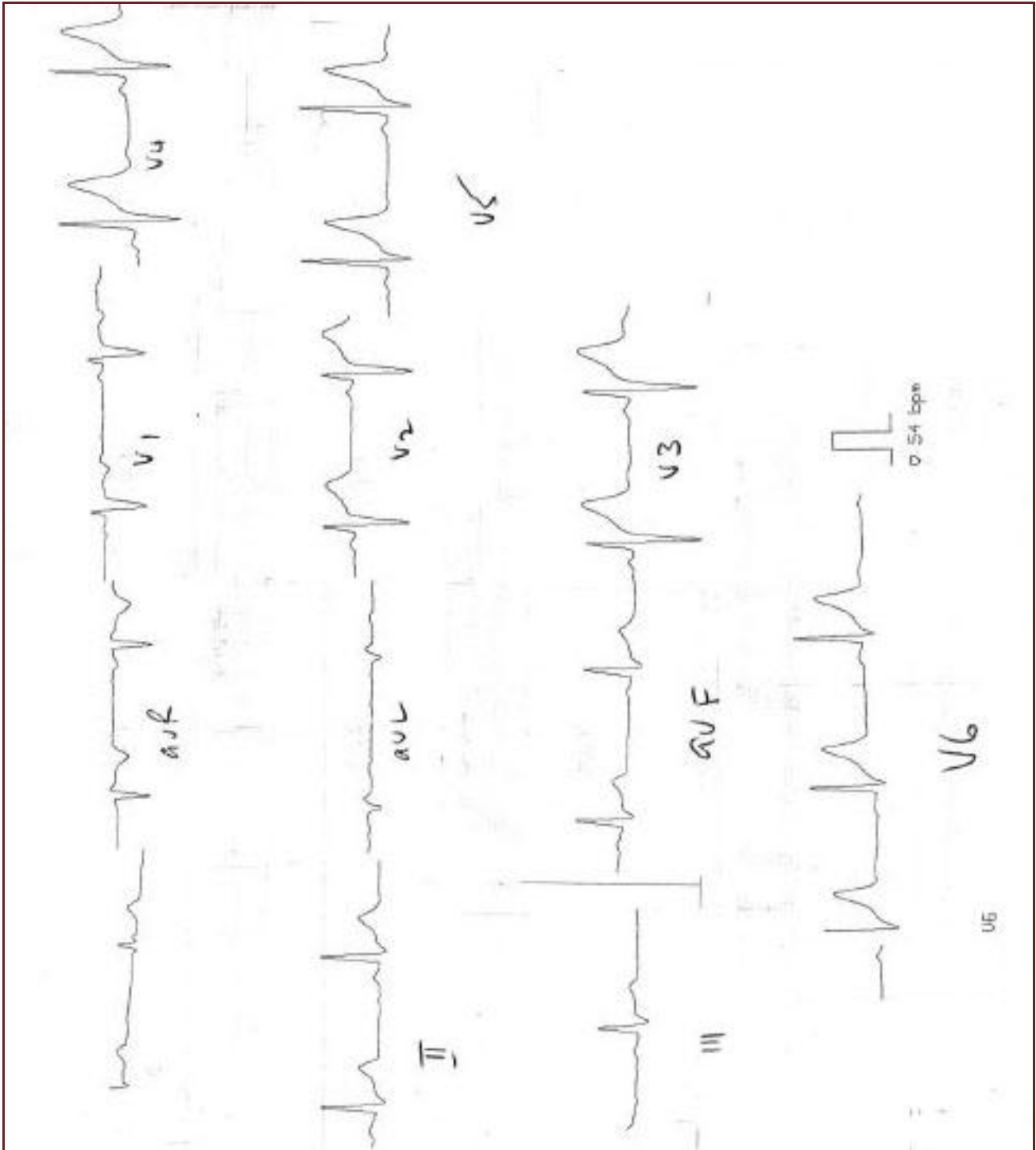
30 year old male, class 1 medical certificate applicant.

ECG self-report: "Normal sinus rhythm. Nonspecific intraventricular block". CAA cardiologist review, two years later at time of subsequent medical certificate application, confirms non-specific intraventricular conduction defect and recommends echocardiography.

Issued unrestricted class 1 medical certificate.

Quiz ECG 5

20 June 1995 (Eleven years ago)



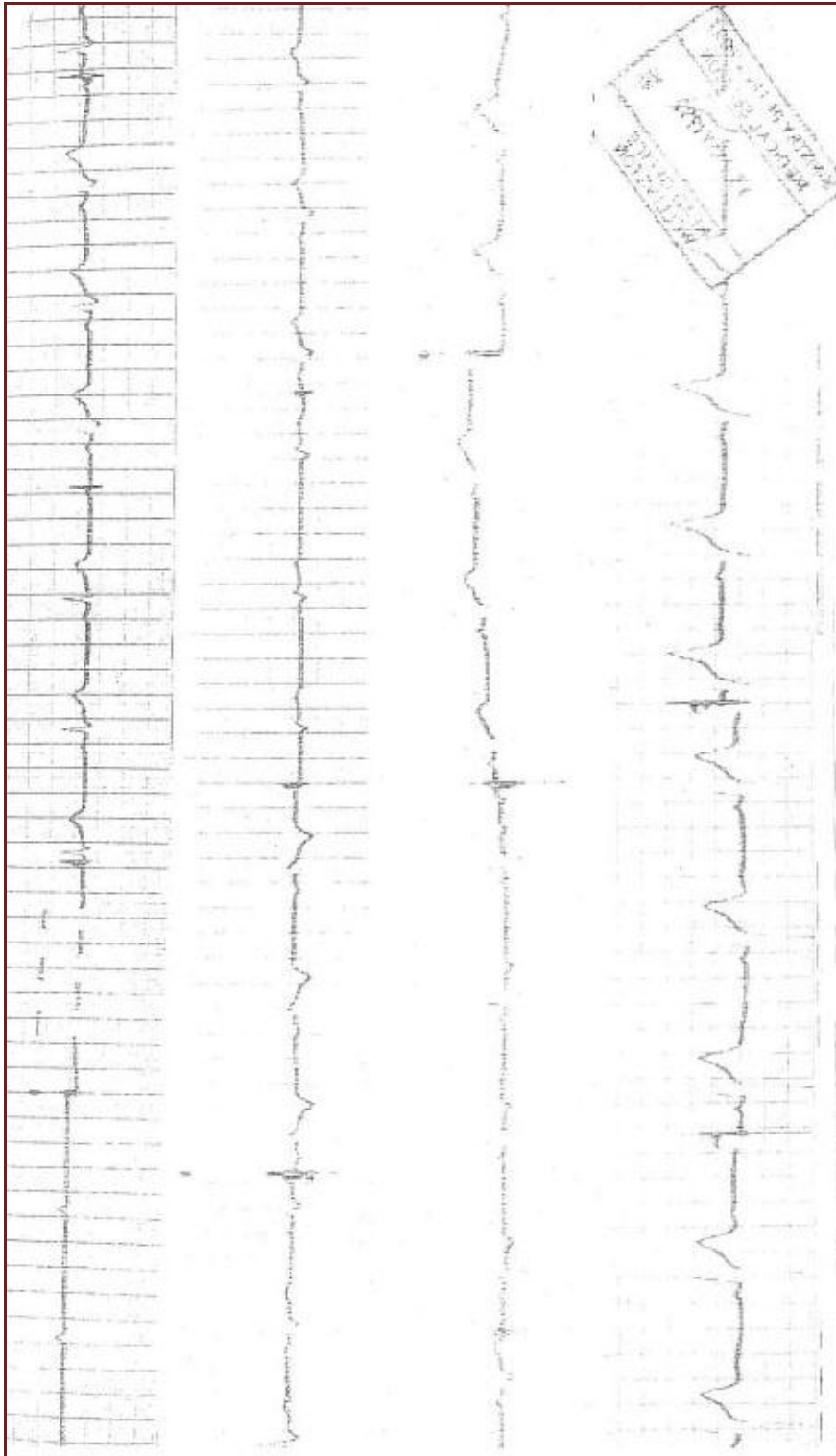
25 year old male, class 1 medical certificate applicant.

Reported by ME: "Normal ECG".

Issued unrestricted class 1 medical certificate.

Quiz ECG 6

13 May 1992 (Fourteen years ago)



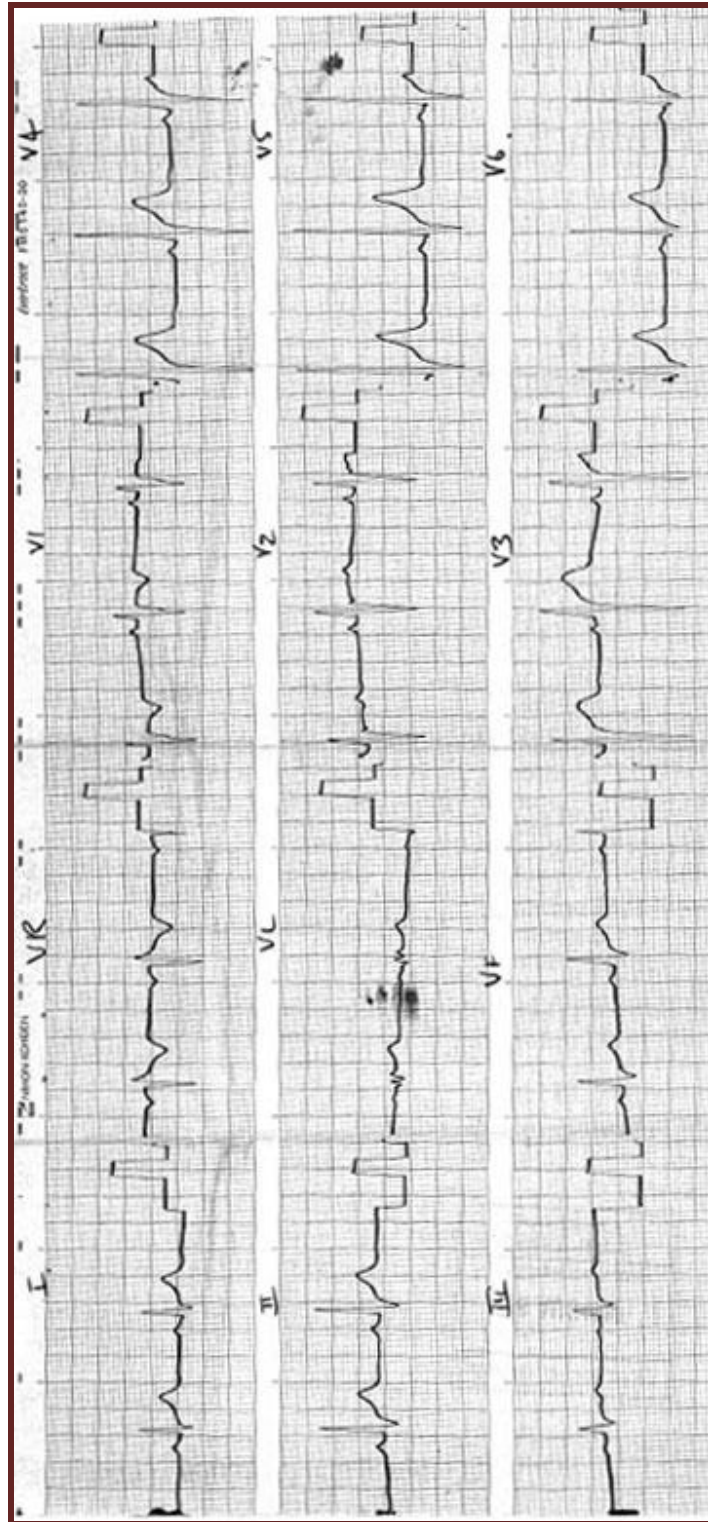
22 year old male, class 1 medical assessment applicant.

Poor quality tracing. Reported (possibly ME, but not clear): "Normal ECG".

Assessed as fit class 1 for maximal validity period.

Quiz ECG 7

25 August 1987 (First ECG on file, nineteen years ago)



17 year old male, PPL medical assessment for student pilot licence.

Cardiologist report: "Sinus rhythm. 60 bpm. 45 degree frontal plane axis. 0.16s PR interval. 0.10s QRS interval. Within normal limits".

Assessed as fit for PPL for 4 years.